International multicenter experience with peroral endoscopic myotomy for the treatment of spastic esophageal disorders refractory to medical therapy (with video) CME

Mouen A. Khashab, MD,[1] Ahmed A. Messallam, MD,[1] Manabu Onimaru, MD, PhD,[2] Ezra N. Teitelbaum, MD,[3] Michael B. Ujiki, MD,[4] Matthew E. Gitelis, BS,[4] Rani J. Modayil, MD,[5] Eric S. Hungness, MD,[3] Stavros N. Stavropoulos, MD,[5] Mohamad H. El Zein, MD,[1] Hironari Shiwaku, MD,[6] Rastislav Kunda, MD,[7] Alessandro Repici, MD,[8] Hitomi Minami, MD, PhD,[9] Philip W. Chiu, MD,[10] Jeffrey Ponsky, MD,[11] Vivek Kumbhari, MD,[1] Payal Saxena, MD,[1] Amit P. Maydeo, MD,[12] Haruhiro Inoue, MD, PhD[2]

Baltimore, Maryland, USA

Background: Limited data exist on the use of peroral endoscopic myotomy (POEM) for therapy of spastic esophageal disorders (SEDs).

Objective: To study the efficacy and safety of POEM for the treatment of patients with diffuse esophageal spasm, jackhammer esophagus, or type III (spastic) achalasia.

Design: Retrospective study.

Setting: International, multicenter, academic institutions.

Patients: All patients who underwent POEM for treatment of SEDs refractory to medical therapy at 11 centers were included.

Interventions: POEM.

Main Outcome Measurements: Eckardt score and adverse events.

Results: A total of 73 patients underwent POEM for treatment of SEDs (diffuse esophageal spasm 9, jackhammer esophagus 10, spastic achalasia 54). POEM was successfully completed in all patients, with a mean procedural time of 118 minutes. The mean length of the submucosal tunnel was 19 cm, and the mean myotomy length was 16 cm. A total of 8 adverse events (11%) occurred, with 5 rated as mild, 3 moderate, and 0 severe. The mean length of hospital stay was 3.4 days. There was a significant decrease in Eckardt scores after POEM (6.71 vs 1.13; $P = .0001$). Overall, clinical response was observed in 93% of patients during a mean follow-up of 234 days. Chest pain significantly improved in 87% of patients who reported chest pain before POEM. Repeat manometry after POEM was available in 44 patients and showed resolution of initial manometric abnormalities in all cases.

Limitations: Retrospective design and selection bias.

Conclusion: POEM offers a logical therapeutic modality for patients with SEDs refractory to medical therapy. Results from this international study suggest POEM as an effective and safe platform for these patients. (Gastrointest Endosc 2015;81:1170-7.)

(footnotes appear on last page of article)

This video can be viewed directly from the GIE website or by using the QR code and your mobile device. Download a free QR code scanner by searching "QR Scanner" in your mobile device's app store.

In the current iteration of the Chicago classification[1] of esophageal motility disorders, spastic esophageal disorders (SEDs) include spastic (type III) achalasia, diffuse esophageal spasm (DES), and hypercontractile (jackhammer) esophagus. Despite differences in pathophysiology, these disorders share many similarities in their clinical presentations, including dysphagia, chest pain, regurgitation, and/or heartburn. The identification of these spastic disorders is based on the contractile pattern observed by using

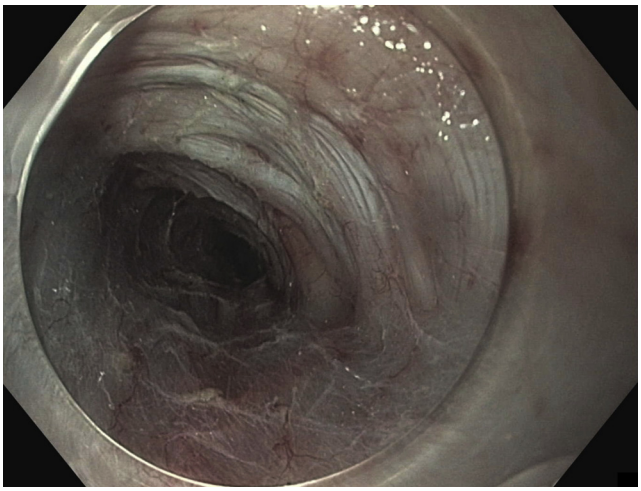

Figure 1. Long submucosal tunnel performed during peroral endoscopic myotomy performed for treatment of a patient with a spastic esophageal disorder.

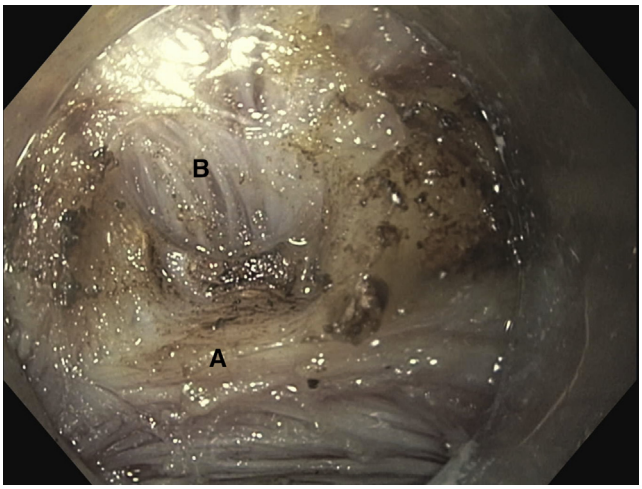

Figure 2. A, Selective inner circular myotomy during peroral endoscopic myotomy performed in a patient with jackhammer esophagus. **B,** Longitudinal muscle is preserved.

high-resolution manometry (HRM) with esophageal pressure topography.

With the more refined criteria of the Chicago classification,[1] the combined prevalence of DES, spastic achalasia, and jackhammer esophagus is approximately 2%.[2] DES is characterized by normal mean integrated relaxation pressure (IRP) and ≥20% premature contractions. Spastic achalasia is characterized by a mean IRP greater than the upper limit of normal (15 mm Hg), no normal peristalsis, preserved fragments of distal peristalsis, or premature (spastic) contractions with ≥20% of swallows. Jackhammer esophagus is an extreme pattern of hypercontractility and is defined manometrically as ≥1 swallow with a distal contractile integral (DCI, the metric of contractile vigor) >8000 mm Hg-s-cm.[3] Jackhammer esophagus may be associated with esophagogastric junction outflow obstruction, which can be associated with hypercontractile swallows.[2] Management of these SEDs is challenging. Symptoms such as chest pain are due to hypertensive contractions in the esophageal body, and standard pharmacologic and endoscopic therapy (pneumatic dilatation, botulinum toxin injection) fail in as many as 74% of patients.[4]

Peroral endoscopic myotomy (POEM) was first described in a swine model[5]; 5 years later, >5000 clinical cases have been performed in several centers across the world as another treatment modality for achalasia. Initial clinical data from Asia, Europe, and the United States has demonstrated the effectiveness and safety of this procedure when performed by experienced endoscopists.[6-12] POEM typically is performed for the treatment of achalasia. However, POEM is potentially an ideal endoscopic therapy for refractory SEDs because it not only allows myotomy of the lower esophageal sphincter (LES) but also of the esophageal body, where the hypertensive contractions occur.

Shiwaku et al[13] previously reported successful treatment of a patient with DES by POEM in which a 17-cm myotomy was performed. Sharata et al[14] reported successful treatment of 2 patients with DES and 4 patients with nutcracker esophagus by POEM. We have previously reported on successful treatment of a patient with jackhammer esophagus by using POEM and suggested POEM as a platform for the treatment of SED refractory to medical therapy.[15] Here we present an international multicenter experience with the use of POEM for the treatment of SED.

PATIENTS AND METHODS

This retrospective study was approved by the Institutional Review Board for Human Research and complied with Health Insurance Portability and Accountability Act regulations at each institution. All patients who underwent POEM for treatment of SED refractory to medical therapy at 11 centers (5 United States, 2 European, and 4 Asian) between January 2011 and November 2013 were included. Diagnosis was based on manometric findings. Relevant clinical (chest pain, Eckardt score), manometric (type of SED, LES pressure, proximal extent of hypertensive contractions), and endoscopic (length of submucosal tunnel, length of myotomy) data were abstracted. Symptoms before and after the procedures (eg, Eckardt scores) and manometry also were recorded. Clinical response was defined by improvement of symptoms and decrease in Eckardt score to ≤3. Chest pain was reported as severe if it occurred daily, moderate if it occurred occasionally, and mild if it occurred rarely. Results of esophageal acid exposure testing after POEM were collected when available, and positive testing results were defined as a DeMeester score of >14.72. GERD was diagnosed by the

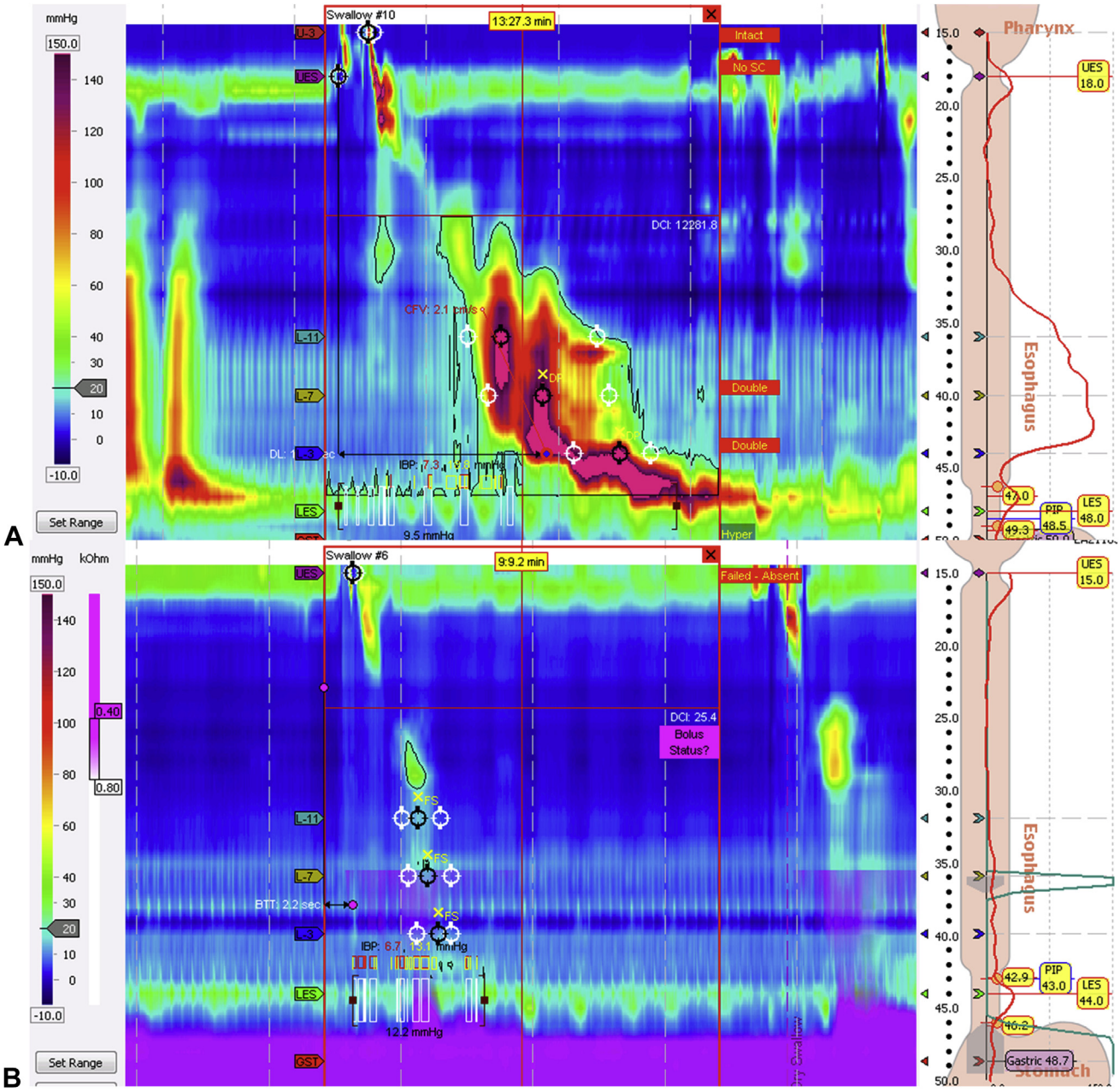

Figure 3. A, Esophageal manometry depicting resolution of initial manometric abnormalities after peroral endoscopic myotomy in a patient with jackhammer esophagus. **B,** Preprocedure evidence of spastic hypercontractile swallow, with distal contractile integral >12,000 mm Hg-s-cm, consistent with jackhammer esophagus. The amplitude is drastically reduced by myotomy, and the spastic jackhammer esophagus is relieved after peroral endoscopic myotomy.

presence of symptoms or esophagitis on follow-up upper endoscopy. Adverse events were graded according to the American Society for Gastrointestinal Endoscopy lexicon severity grading system.[16]

All procedures were performed by using high-definition gastroscopes fitted with transparent caps, with patients under general anesthesia and insufflation by using carbon dioxide. Intravenous antibiotics were administered before the procedure. Briefly, a submucosal bleb was created on the anterior or posterior wall at the discretion of the endoscopist in the upper or mid esophagus by using saline solution and 0.25% indigo carmine solution. A 1.5 cm to 2 cm longitudinal mucosal incision was made with either a triangular tip knife (KD 640L; Olympus America, Center Valley, Pa) or hybrid knife (ERBE, Tübingen, Germany). The endoscope was then maneuvered into the submucosal space, and the knife was used to dissect the submucosal fibers. Repeated injection of saline solution mixed with indigo carmine was performed to enhance the demarcation between the submucosal layer and muscularis propria

TABLE 1. Baseline characteristics of patients who underwent POEM

No. of patients	73
Age, mean (range), y	58.6 (17-89)
Female, %	46.5
DES, no.	9
Jackhammer esophagus, no.	10
Spastic achalasia, no.	54
Before-POEM Eckardt score, mean (range)	6.73 (1-12)
Symptoms, no. (%)	
Chest pain present	49 (67.1)
Dysphagia	73 (100)
Regurgitation	62 (84.9)
Weight loss, kg, no. (%)	
None	26 (35.6)
<5	12 (16.4)
5-10	13 (17.8)
>10	22 (30.1)
Prior intervention, no.	
Pneumatic dilation	15
Botulinum toxin injection	7
Laparoscopic Heller myotomy	3
Open transabdominal Heller myotomy	1

POEM, Peroral endoscopic myotomy; *DES,* diffuse esophageal spasm.

TABLE 2. Procedural characteristics and outcomes

Submucosal tunnel length, mean (range), cm	19 (9-30)
Myotomy length, mean (range) cm	16 (7-26)
Length of hospital stay, mean (range) d	3.4 (1-23)
Adverse events, no.	
Total	8
Mild	5
Moderate	3
Clinical response, no. (%)	68 (93.2)
After-POEM Eckardt score, mean (range)	1.13 (0-9)

POEM, Peroral endoscopic myotomy.

whenever the submucosal dissection plane became unclear. Care was taken with orientation of the endoscope to ensure that the mucosal layer was not injured during dissection as the submucosal tunnel was extended, passing the LES and 2 cm to 3 cm into the proximal stomach (Fig. 1). Subsequently, either selective myotomy of the inner circular muscle bundles or full-thickness myotomy was performed starting 2 cm distal to the mucosal entry point and at the discretion of the endoscopist (Fig. 2). Larger vessels in the submucosa were coagulated by using the Coagrasper (Olympus) in soft coagulation mode. Mucosal entry was then closed by using endoscopic clips or suturing. Air insufflation was avoided to minimize the risk of pneumothorax, pneumomediastinum, and pneumoperitoneum. The length of the myotomy was based on the review of HRM and proximal extent of hypertensive contractions (Video 1, available online at www.giejournal.org).

All patients were subsequently admitted for inpatient hospital observation. Esophagrams were obtained the following day, and soft diets were begun after esophageal leakage was excluded. Patients were advised to remain on a soft diet for 2 weeks, after which a regular diet could be started. Follow-up included clinic visits to assess for delayed adverse events and clinical response (chest pain and Eckardt score) in addition to esophageal acid exposure testing and repeat HRM (Fig. 3).

Results are reported as mean ± standard deviation and/or range for quantitative variables and absolute and relative frequencies for categorical variables. Outcomes between parameters were compared before and after procedures by using the *t* test (paired *t* test where applicable) for continuous variables and the chi-square test for categorical variables. Chi-square test and logistic regression analysis were used to compare patient and procedural characteristics across the 3 SED types. Statistical significance was based on 2-sided, design-based tests evaluated at $\alpha = 0.05$. Statistical analysis was performed by using STATA version 13 (Stata Corporation, Dallas, Tex).

RESULTS

A total of 73 patients (mean age 58.6 years, 46.5% female) underwent POEM for treatment of SEDs (DES 9 [12.3%], jackhammer esophagus 10 [13.7%], type III achalasia 54 [74%]). Patients presented for POEM after an average of 5.1 years since initial diagnosis. Chest pain was present in 49 patients (67.1%) and 26 (42.6%) reported it as moderate and/or severe. All patients had dysphagia, and 62 (84.9%) reported symptoms of regurgitation (Table 1). Before-POEM manometry revealed a mean 4-second IRP of 26.1 ± 16 mm Hg and mean DCI of 13,163 mm Hg-s-cm among those with jackhammer esophagus.

TABLE 3. Adverse events of POEM

Adverse event	Frequency	Severity grade	Management
Pulmonary embolism	1	Moderate	Anticoagulation
Mucosotomy	2	Mild (1)	Endoscopic clips and endoloop
		Moderate (1)	
Infectious esophagitis (due to clip dislodgment)	1	Mild	Antibiotics
Surgical/subcutaneous emphysema	2	Mild (1)	Self-resolved/conservative treatment
		Moderate (1)	
Chest/epigastric pain requiring admission	2	Mild	Self-resolved/conservative treatment

POEM, Peroral endoscopic myotomy.

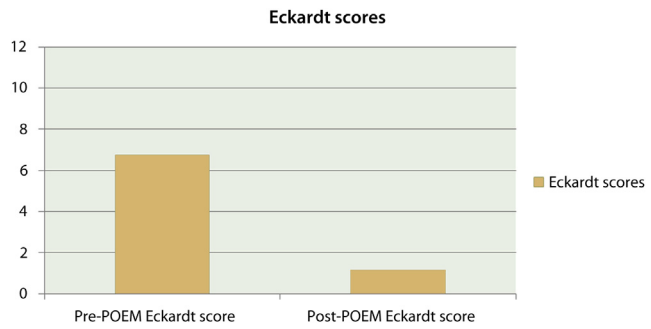

Figure 4. Bar chart documenting significant decrease in mean Eckardt score after peroral endoscopic myotomy in 73 patients with spastic esophageal disorders. *POEM,* peroral endoscopic myotomy.

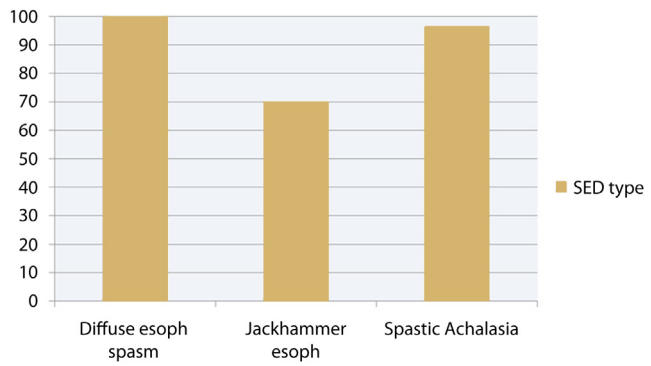

Figure 5. Bar chart showing significantly higher clinical response in patients with spastic achalasia and diffuse esophageal spasm as compared with patients with jackhammer esophagus. *SED,* spastic esophageal disorder.

POEM was successfully completed in all patients via an anterior approach in 66 and posterior approach in 7, with a mean procedure time of 118 minutes (range 43-345 minutes). Selective inner circular myotomy was performed in 64 patients (87.7%), whereas full-thickness myotomy was carried out in the remaining 9 patients. The mean length of the submucosal tunnel was 19 cm (range 9-30 cm). The mean myotomy length was 16 cm (range 7-26 cm) (esophageal 13.4 cm, cardia 2.6 cm) (Table 2). A total of 8 adverse events (11%) occurred, with 5 rated as mild, 3 moderate, and none severe (Table 3). The mean length of hospital stay was 3.4 days (range 1-23 days).

There was a significant decrease in the mean Eckardt score after POEM (6.73 vs 1.13; $P < .001$) (Fig. 4). Overall, clinical response was observed in 93.2% of patients during a mean follow-up of 234 days (range 7-1017 days). Chest pain clinically improved in 87% of patients who reported chest pain before POEM. Formal pH testing was performed in 19 patients and results were positive in 13 (68.4%). Symptomatic acid reflux was present in 6 patients (8.2%). Repeat manometry after POEM was available in 44 patients and showed resolution of initial manometric abnormalities in all (100%) patients.

Patients with spastic achalasia (96.3%) and DES (100%) responded significantly better than those with jackhammer esophagus (70%) ($P = .05$ for both comparisons) (Fig. 5). Similarly, mean postprocedural Eckardt scores were significantly less in patients with spastic achalasia (score = 0.86) and DES (score = 1), as compared with those with jackhammer esophagus (score = 2.6) ($P = .01$ for both comparisons) (Table 4).

DISCUSSION

Recent advances in natural orifice transluminal endoscopic surgery[17-19] and the improvement of devices for endoscopic submucosal dissection have culminated in endoluminal approaches to treat achalasia. Submucosal tunneling was initially described by Sumiyama et al,[20] whereas POEM was first described by Pasricha et al[5] in 2007. Inoue et al[6] championed translating this innovative procedure into clinical care. POEM is traditionally performed for achalasia. The role of POEM in the management of patients with DES and jackhammer esophagus is largely unknown. Similarly, published reports on POEM for achalasia either included few patients with spastic type or did not stratify results according to achalasia subtype.

TABLE 4. Patient and procedural characteristics stratified by type of spastic esophageal disorder

Characteristic	DES (n = 9)	Jackhammer (n = 10)	Spastic achalasia (n = 54)	*P* value
Age, mean ± SD, (range), y	70.7 ± 16.1 (41-86)	53.4 ± 12.6 (28-68)	57.6 ± 19.3 (17-89)	.09
Female (%)	33.3	80	42.6	.10
Before-POEM Eckardt score, mean ± SD, (range)	6.9 ± 3.3 (2-12)	8.4 ± 1.9 (6-11)	6.4 ± 2.2 (1-12)	.05*
Chest pain present, no. (%)	7 (77.8)	9 (90)	33 (61.1)	.20
Submucosal tunnel length, mean (range), cm	19.7 (13-26)	18.4 (12-22)	19.1 (9-30)	.82
Myotomy length, mean, (range), cm	16.6 (10-23)	14.3 (8-19)	16.4 (7-26)	.38
Length of hospital stay, (range), d	5.4 (1-23)	3.3 (1-10)	3.1 (1-9)	.10
Total adverse events, no. (%)	2 (22.2)	2 (20)	4 (7.4)	.29
Mild	1	2	2	.21
Moderate	1	0	2	.36
Clinical response, no. (%)	9 (100)	7 (70)	52 (96.3)	.05*
After-POEM Eckardt score, mean (range)	1 (0-3)	2.6 (0-6)	0.86 (0-9)	.01*

DES, Diffuse esophageal spasm; *SD,* standard deviation; *POEM,* peroral endoscopic myotomy.
*Comparisons are for spastic achalasia and DES versus jackhammer esophagus.

Heller myotomy is an established treatment of achalasia, which as with pneumatic dilation, has a lower response rate in patients with spastic achalasia.[21,22] This might be explained by the disease involving not only the LES but also the esophageal body. Long surgical myotomy extending from the LES proximally onto the esophageal body has been used to treat patients with spastic achalasia and the other SEDs. The extent of the myotomy may be guided by manometric findings.[4,23] In a series of 20 patients with extended surgical myotomy for achalasia (14 cm on the esophagus and 2 cm below the esophagogastric junction), dysphagia and chest pain were significantly improved after a median follow-up of 50 months.[24] Patti et al[4] compared outcomes of patients with DES and nutcracker esophagus treated by surgical myotomy with those treated medically, and their study suggested that surgical treatment might be more effective than medical treatment.

Given the data suggesting that surgical myotomy may be effective in treating patients with SED, we proposed POEM as a less-invasive treatment modality for those difficult-to-treat patients. The main advantage of POEM over surgery in this setting is that it allows access to the entire esophageal body, and, thus, an extensive myotomy can be performed without limitations. Access to the proximal esophageal body may not be possible through a laparoscopic approach, which may explain the unfavorable response of type III achalasia patients to Heller myotomy.[21,22]

In the current report, we described an international multicenter experience by using POEM as a treatment modality for patients with various SEDs. All patients were refractory to standard medical management. Most patients had moderate-to-severe symptoms, and a majority had chest pain, which is a typical manifestation of these spastic disorders. POEM was carried out in standard fashion, but an extensive myotomy was performed. The proximal extent of the myotomy was guided by findings on HRM, and the mean myotomy length was 16 cm, which is double the length that is typically performed during POEM done for achalasia. Also, careful endoscopic inspection typically confirms the proximal extent of these contractions. Procedures were completed during an average of 118 minutes, but longer procedure times may be required because of the extended length of the required myotomy. In the current report, procedure times ranged between 43 minutes and 345 minutes.

Although the current report encompassed difficult-to-treat patients (ie, refractory to medical therapy, majority with significant chest pain), clinical response was observed in 93% of patients, and there was a statistically significant decrease in the mean Eckardt score after POEM (6.71 vs 0.81; $P = .0001$). Importantly, the majority of patients underwent follow-up HRM, which showed resolution of initial manometric abnormalities in all patients.

POEM was safe, and adverse events were uncommon (11%) (Table 3). Importantly, there were no severe adverse events. Symptomatic GERD occurred in a minority of patients (8.2%), although abnormal esophageal acid exposure was seen more frequently (13 of 19 patients who underwent formal pH testing after POEM). Selection bias may

have overestimated the risk of abnormal acid exposure. Nonetheless, asymptomatic acid reflux is common after POEM, and we recommend that all patients who undergo POEM get subsequent esophageal acid exposure testing, even if they are asymptomatic. Patients with positive test results should be treated with proton pump inhibitors to avoid long-term GERD adverse events (eg, Barrett's esophagus, peptic strictures).

Some patients with SEDs have concomitant esophagogastric junction outflow obstruction, based on HRM criteria.[2] By definition, patients with type III achalasia have outflow obstruction. Patients with DES do not manifest this abnormal manometric finding. Patients with jackhammer esophagus may have esophagogastric junction outflow obstruction.[2] It is arguable whether patients without outflow obstruction require myotomy of the LES. Myotomy of the esophageal body induces aperistalsis, and this may result in paradoxical dysphagia in patients who do not undergo LES myotomy. The inclusion of the LES seems warranted by the potential after-effects of myotomy, even in the setting of normal LES pressure, to prevent postoperative dysphagia.[25]

Our results also suggest that jackhammer esophagus represents a more difficult entity to treat as compared with both spastic achalasia and DES. Nonetheless, the majority of patients with jackhammer esophagus (70%) experienced a clinical response. The reason for the diminished response to POEM in these patients is unknown but may be related to extreme contractility in the esophageal body. The value of concomitant bilateral (anterior and posterior) myotomy in patients with jackhammer esophagus needs to be determined.

Our study has a number of limitations. In particular, this was a retrospective study with inherent design limitations. Selection bias may have occurred because of the nonrandomized nature of the study. Inclusion of multiple centers may have introduced heterogeneity, but at the same time this renders the study results more widely applicable. Endoscopists were experts in submucosal endoscopy, and results may not be applicable to endoscopists with less experience in this field. Eckardt scores were used to measure patient outcomes, although these have not been validated in patients without achalasia. Last, formal follow-up pH and manometric testing were not formally obtained in all patients.

Nevertheless, POEM offers a logical therapeutic platform for patients with SEDs refractory to medical therapy. POEM experts have proposed POEM as a useful treatment for DES, and motility experts have suggested that POEM with extensive myotomy may play a role in SED cases with treatment failure. Here, we report successful treatment of patients with severe symptoms of SED by POEM and extensive myotomy, and we suggest POEM as an effective and safe therapeutic platform for the treatment of patients with SEDs and moderate to severe symptoms refractory to medical therapy. Prospective and randomized trials are needed to confirm the positive findings of this trial.

REFERENCES

1. Bredenoord AJ, Fox M, Kahrilas PJ, et al. Chicago classification criteria of esophageal motility disorders defined in high resolution esophageal pressure topography. Neurogastroenterol Motil 2012;24(suppl 1):57-65.
2. Roman S, Kahrilas PJ. Management of spastic disorders of the esophagus. Gastroenterol Clin North Am 2013;42:27-43.
3. Roman S, Pandolfino JE, Chen J, et al. Phenotypes and clinical context of hypercontractility in high-resolution esophageal pressure topography (EPT). Am J Gastroenterol 2012;107:37-45.
4. Patti MG, Pellegrini CA, Arcerito M, et al. Comparison of medical and minimally invasive surgical therapy for primary esophageal motility disorders. Arch Surg 1995;130:609-15; discussion 15-6.
5. Pasricha PJ, Hawari R, Ahmed I, et al. Submucosal endoscopic esophageal myotomy: a novel experimental approach for the treatment of achalasia. Endoscopy 2007;39:761-4.
6. Inoue H, Minami H, Kobayashi Y, et al. Peroral endoscopic myotomy (POEM) for esophageal achalasia. Endoscopy 2010;42:265-71.
7. von Renteln D, Inoue H, Minami H, et al. Peroral endoscopic myotomy for the treatment of achalasia: a prospective single center study. Am J Gastroenterol 2012;107:411-7.
8. Costamagna G, Marchese M, Familiari P, et al. Peroral endoscopic myotomy (POEM) for oesophageal achalasia: preliminary results in humans. Dig Liver Dis 2012;44:827-32.
9. Maselli R, Inoue H, Misawa M, et al. Peroral endoscopic myotomy (POEM) in a 3-year-old girl with severe growth retardation, achalasia, and Down syndrome. Endoscopy 2012;44(suppl 2) UCTN:E285-7. Epub 2012 Aug 29.
10. Kurian AA, Dunst CM, Sharata A, et al. Peroral endoscopic esophageal myotomy: defining the learning curve. Gastrointest Endosc 2013;77:719-25.
11. Swanstrom LL, Rieder E, Dunst CM. A stepwise approach and early clinical experience in peroral endoscopic myotomy for the treatment of achalasia and esophageal motility disorders. J Am Coll Surg 2011;213:751-6.
12. Saxena P, Chavez YH, Valeshabad AK, et al. An alternative method for mucosal flap closure during POEM using an over-the-scope clipping device (with video). Endoscopy 2013;45:579-81.
13. Shiwaku H, Inoue H, Beppu R, et al. Successful treatment of diffuse esophageal spasm by peroral endoscopic myotomy. Gastrointest Endosc 2013;77:149-50.
14. Sharata A, Kurian AA, Dunst CM, et al. Peroral endoscopic myotomy (POEM) is safe and effective in the setting of prior endoscopic intervention. J Gastrointest Surg 2013;17:1188-92.
15. Khashab MA, Saxena P, Kumbhari V, et al. Peroral endoscopic myotomy as a platform for the treatment of spastic esophageal disorders refractory to medical therapy (with video). Gastrointest Endosc 2014;79:136-9.
16. Cotton PB, Eisen GM, Aabakken L, et al. A lexicon for endoscopic adverse events: report of an ASGE workshop. Gastrointest Endosc 2010;71:446-54.
17. Kalloo AN, Singh VK, Jagannath SB, et al. Flexible transgastric peritoneoscopy: a novel approach to diagnostic and therapeutic interventions in the peritoneal cavity. Gastrointest Endosc 2004;60:114-7.
18. Khashab MA, Kalloo AN. NOTES: current status and new horizons. Gastroenterology 2012;142:704-10.e1.
19. Khashab MA, Kalloo AN. Critical analysis of hot topics in NOTES. Nat Rev Gastroenterol Hepatol 2012;8:565-72.
20. Sumiyama K, Gostout CJ, Rajan E, et al. Submucosal endoscopy with mucosal flap safety valve. Gastrointest Endosc 2007;65:688-94.
21. Pandolfino JE, Kwiatek MA, Nealis T, et al. Achalasia: a new clinically relevant classification by high-resolution manometry. Gastroenterology 2008;135:1526-33.

22. Rohof WO, Salvador R, Annese V, et al. Outcomes of treatment for achalasia depend on manometric subtype. Gastroenterology 2013;144:718-25; quiz e13-4.
23. Ellis FH Jr. Esophagomyotomy for noncardiac chest pain resulting from diffuse esophageal spasm and related disorders. Am J Med 1992;92:129-131S.
24. Leconte M, Douard R, Gaudric M, et al. Functional results after extended myotomy for diffuse oesophageal spasm. Br J Surg 2007;94:1113-8.
25. Henderson RD. Diffuse esophageal spasm. Surg Clin North Am 1983;63:951-62.

Abbreviations: DCI, distal contractile integral; DES, diffuse esophageal spasm; HRM, high-resolution manometry; IRP, integrated relaxation pressure; LES, lower esophageal sphincter; POEM, peroral endoscopic myotomy; SED, spastic esophageal disorder.

DISCLOSURE: *M. Khashab is a consultant for Boston Scientific and Olympus America and has received research support from Cook Medical. H. Inoue is a founding member, equity holder, and consultant for Apollo Endosurgery. No other financial relationships relevant to this article were disclosed.*

See CME section; p. 1237.

0016-5107/$36.00
http://dx.doi.org/10.1016/j.gie.2014.10.011

Received May 19, 2014. Accepted October 9, 2014.

Current affiliations: Johns Hopkins Medical Institute, Baltimore, Maryland, USA (1), Showa University Northern Yokohama Hospital, Yokohama, Japan (2), Northwestern University, Chicago (3), North Shore University Health System, Evanston, Illinois (4), Winthrop University Hospital, Mineola, New York, USA (5), Fukuoka University Faculty of Medicine, Fukuoka, Japan (6), Aarhus University Hospital, Aarhus, Denmark (7), Humanitas Research Hospital, Milano, Italy (8), Nagasaki University Hospital, Nagasaki, Japan (9), Institute of Digestive Disease, The Chinese University of Hong Kong, Shatin, Hong Kong, China (10), University Hospitals Case Medical Center, Cleveland, Ohio, USA (11), Baladota Institute of Digestive Sciences, Mumbai, India (12).

Reprint requests: Mouen A. Khashab, MD, Assistant Professor of Medicine, Director of Therapeutic Endoscopy, Johns Hopkins Hospital, 1800 Orleans St, Suite 7125 B, Baltimore, MD 21205.

If you would like to chat with an author of this article, you may contact Dr Khashab at mkhasha1@jhmi.edu.